

Ultrasound in the assessment of respiratory failure and shock in the ICU

Dr Sahajal Dhooria

Outline

- Point of care USG
- Basics of Lung USG
- USG in the assessment of acute respiratory failure
- USG in the assessment of shock
- Summary

Point of Care USG

- Ultrasonography brought to the patient and performed by the provider in real time
- Findings directly correlated with the patient's presenting signs and symptoms
- Easily repeatable if the patient's condition changes

Sonography versus Focussed Sonography

FAST

- Focussed Assessment with Sonography for Trauma
- May be completed in less than 5 minutes
- Sensitivity of 73 to 99%, a specificity of 94 to 98%, and an overall accuracy of 90 to 98% for clinically significant intraabdominal injury in trauma¹
- Avoids unnecessary CTs and DPLs

¹Melanson SW. Dallas: ACEP, 2003:127-45.

Emergency
physician (EP)/
Critical Care
Physician (CCP)

versus

Radiologist/
Cardiologist

Pericardial Effusion

- Trained emergency physicians performed focused cardiac ultrasonographic examination on 515 patients
- Scans reviewed by cardiologist
- Sensitivity of 96% and a specificity of 98% for the diagnosis of a pericardial effusion, with 93% having technically adequate scans.

Mandavia D et al. Ann Emerg Med 2001;38(4):377–82

Left Ventricular Function

- Appropriately trained emergency physicians using only visual qualitative estimation of left ventricular function could accurately assess the degree of left ventricular dysfunction when compared with formal echocardiographic calculations

CVP

- Assessment of the central venous pressure by point-of-care physicians correlated 83.3% of the time with the formal assessment of the same ultrasonographic images by a staff cardiologist.

DVT

- Several studies have reported that emergency physicians and other clinicians can be accurate and fast in their diagnosis of DVT with the help of USG

Shiver SA et al. Am J Emerg Med 2010;28(3): 354–8.

McIlrath ST et al. Am J Emerg Med 2006;24(3):325–8.

- In 2004, a conference on compact ultrasonography hosted by the American Institute of Ultrasound in Medicine (AIUM) concluded that “the concept of an ‘ultrasound stethoscope’ is rapidly moving from the theoretical to reality.”

USG Stethoscope

- Some medical schools are now beginning to provide their students with hand-carried ultrasound equipment for use during clinical rotations

Basics of Lung Ultrasound

LUS-Basics

- Sonographic semiology of lung diseases is based on the recognition of artifacts rather than visualization of real structures.
- Caused by the interaction of the sonographic beam with air, fluids, and tissues.
- Three different sonographic syndromes:
 - Pleural syndrome
 - Interstitial syndrome
 - Alveolar syndrome

Probes

- Curvilinear (2-5 MHz)
- Better penetration, low resolution
- Abdominal imaging

- Linear probe (5-10 MHz)
- Lesser penetration, better resolution
- Superficial structures eg vessels, lung ultrasound

A Lines

- Horizontal lines (roughly parallel to the chest wall)
- Brightly echogenic and located between the rib shadows when the probe is positioned longitudinally
- Normal reverberation artifact
- More prominent in COPD, asthma

Comet Tails

- Comet tails are an ultrasound artifact that arises when ultrasound encounters a small air– fluid interface

B Lines

- Comet tails that extend from the pleural line to the bottom of the screen
- Arise at the border between aerated and compressed lung
- Move synchronously with the lung during respiration and tend to erase A lines

B Lines

- Suggest presence of alveolar interstitial syndrome
- Differentials
 - Pulmonary Edema
 - Pneumonia
 - ARDS
 - Lung contusion
 - Chronic ILD
- Few localised B lines also seen in normal lung

E Lines

- Vertical lines extending from the areas of subcutaneous emphysema deep into the chest
- Can be confused with B lines and thus contribute to misidentification of a pneumothorax
- Should be suspected when subcutaneous emphysema can be palpated on the chest wall and when the vertical lines start at a level external to the ribs

Lung Sliding

- Slight and bright horizontal movement of the pleural line
- More evident during active and passive respiration
- Resolution of the sonograph does not allow distinction between the two pleural layers, and the sliding is an indirect sign indicating the presence of the visceral pleura adhering to the parietal pleura.
- When air separates the two pleural layers, the movement disappears and cannot be detected by LUS. In this case, the parietal pleura is still visualized but does not move.

Causes of Absent Sliding

- Pneumothorax
- Atelectasis
- Main-stem intubation
- ARDS
- Pleural adhesions

Lung Pulse

- Vertical movement of the pleural line synchronous to the cardiac rhythm
- More commonly seen on the left hemithorax than the right
- Caused by transmission of heart beats through consolidated, motionless lung

Lung Pulse

- Commonly present in:
 - Massive atelectasis
 - Main-stem intubation
- Absent in:
 - Pneumothorax
 - Intrapleural air prevents transmission of either horizontal or vertical movements to the parietal pleura. Visualization of a lung pulse excludes a pneumothorax.

Lung Point

- Defined as a location where the lung adheres to the parietal pleura in a patient with a pneumothorax
- Lung sliding seen intermittently i.e. presence of lung sliding in one area and not in adjacent one
- Strong indicator of a pneumothorax

USG in the Assessment of Acute Respiratory Failure

RADiUS¹

- Rapid Assessment of Dyspnea with UltraSound
- 4 different components:
 - Focused cardiac evaluation
 - Focused IVC evaluation
 - Assessment of pleural line
 - Evaluation of thoracic cavity for pleural effusion

¹William M et al. Ultrasound Clin 6 (2011): 261-276

Focused Cardiac Evaluation

- Pericardial effusion
- Cardiac Tamponade
- Left Ventricular Function
- Pulmonary Embolism

Pericardial Effusion

- Almost any cardiac view capable of identifying large pericardial effusions
- Subcostal view convenient for non cardiologists
- Parasternal long-axis view particularly helpful in differentiating pericardial effusion from pleural effusion.
 - Pericardial effusion located posterior to the left ventricle/ left atrium, but anterior to the descending aorta
 - Pleural effusion seen as an anechoic area tracking posterior to the aorta

Pericardial Effusion

- Quantification¹:
 - Small effusions when separation between the heart and parietal pericardium is less than 0.5 cm
 - Moderate effusions are 0.5 cm to 2 cm
 - Large effusion are greater than 2 cm

¹Otto CM. Textbook of clinical echocardiography. China: Saunders Elsevier; 2009. p. 608.

Cardiac Tamponade

- Depends on amount and rapidity of collection of pericardial effusion
- Identified by looking for
 - Right atrial diastolic collapse (RADC)
 - Right ventricular diastolic collapse (RVDC)

Left Ventricular Function

- Visual assessment
- LVEF using M-mode in the parasternal long axis view

Pulmonary Embolism

- Sensitivity 40-70% ¹
- McConnell sign – Reduced function of right ventricle with a normal apex of right ventricle (specificity 94%, NPV 96%)

¹Otto CM. Textbook of clinical echocardiography. China: Saunders Elsevier; 2009. p. 608.

Compression USG

- Looking at the right heart can be combined with a compression ultrasound for DVT
- Less commonly done by emergency physicians

Focused IVC Evaluation

- Collapsibility of IVC- excellent predictor of patient's volume status
- Most consistent locations for measuring IVC collapse:
 - IVC in transverse view at left renal vein level
 - Longitudinal view through liver 2 cm caudal to hepatic vein inlet

IVC and RAP

Table 1
Estimation of right atrial pressure (RAP)

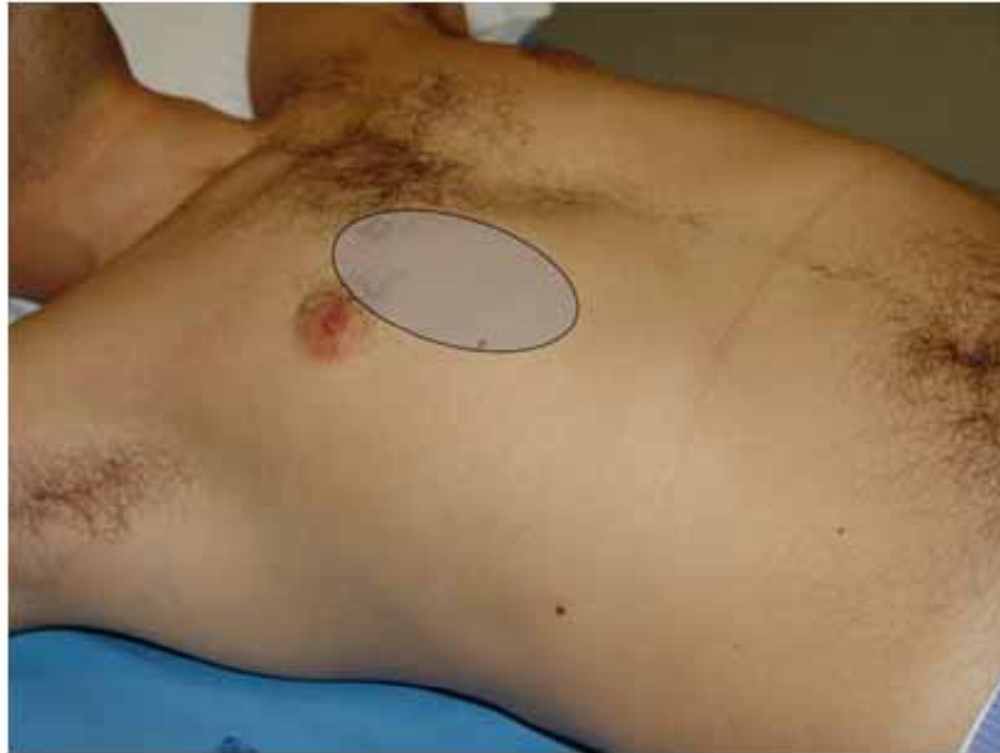IVC Diameter (cm)	% Change with Respiration	Estimated RAP
<1.2	Spontaneous collapse	Volume depletion
<1.7	>50%	0–5 mm Hg
>1.7	>50%	5–10 mm Hg
>1.7	<50%	10–15 mm Hg
>1.7	No change	15–20 mm Hg
Dilated with dilated hepatic veins	No change	>20 mm Hg

¹William M et al. Ultrasound Clin 6 (2011): 261-276

Assessment of the Pleural Line and Other Artifacts

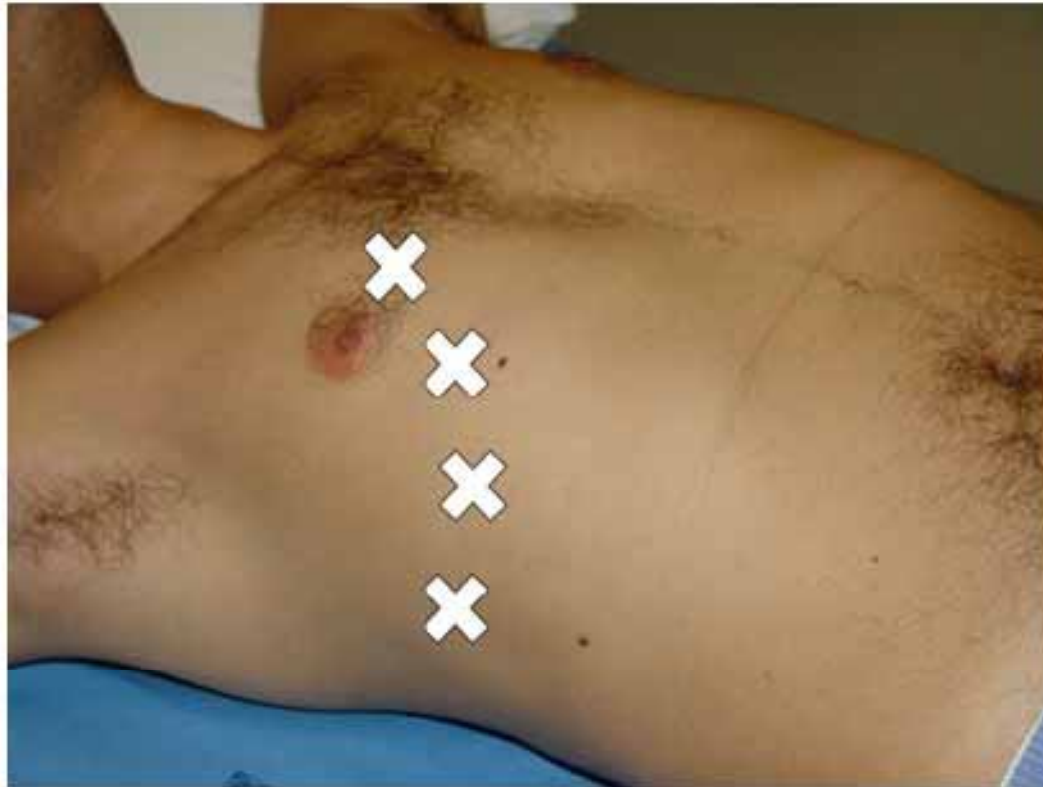- Important part of assessment of respiratory failure
- Can help in differentiating the following conditions:
 - Pneumothorax
 - Pulmonary edema
 - Pneumonia
 - COPD/ Asthma

Probe Positioning



Always begin from this area esp if pneumothorax is a possibility

Probe Positioning



First Step

- Look for Lung Sliding
- Present on anterior-inferior areas of the two hemithoraces in supine patient– NPV of 100% (pneumothorax is ruled out)¹
- Absent lung sliding-- Poor specificity in ICU patients (78%)
- Poor PPV (22%)²
- Consider other differentials

¹Lichtenstein DA et al. Chest 1995; 108:1345–1348

²Lichtenstein DA et al. Chest 2008; 134:117–125

Second Step

- Look for B lines
- Visualisation of even one isolated B line demonstrates adherence of visceral to parietal pleura
- True NPV of 100%¹

¹Lichtenstein D et al. Intensive Care Med 1999; 25:383–388

Third Step

- Look for lung pulse
- In a patient with cardiac activity with absent lung sliding due to massive atelectasis or main-stem intubation, lung pulse is a common finding (sensitivity 93%)¹
- Helps to differentiate between differentials of absent lung sliding

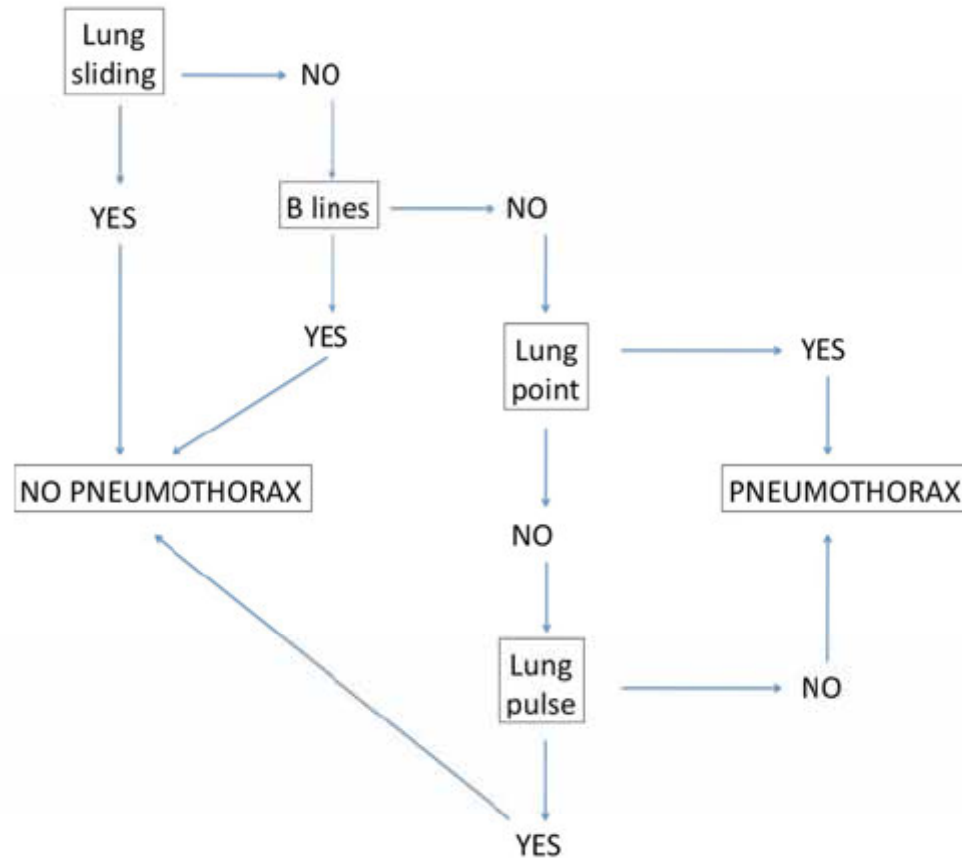
¹Lichtenstein DA et al. Intensive Care Med 2003; 29:2187–2192

Fourth Step

- Look for lung point
- 100% specificity for ruling in pneumothorax¹
- Sensitivity of this sign is low because in the case of pneumothorax with complete retraction of the lung, no lung point is visualised

¹Lichtenstein DA et al. Intensive Care Med 2000; 26:1434–1440

Flowchart



Ultrasound is more sensitive and specific than chest radiography for detection of pneumothorax¹

¹Lichtenstein DA et al. Crit Care Med 2005;33(6):1231–8.

Analysis of artifacts

CHEST[®]

Official publication of the American College of Chest Physicians

Relevance of Lung Ultrasound in the Diagnosis of Acute Respiratory Failure^{*} : The BLUE Protocol

Daniel A. Lichtenstein and Gilbert A. Mezière

Chest 2008;134;117-125; Prepublished online April 10, 2008;
DOI 10.1378/chest.07-2800

The online version of this article, along with updated information and services can be found online on the World Wide Web at:

<http://chestjournal.chestpubs.org/content/134/1/117.full.html>

Supplemental material related to this article is available at:

<http://chestjournal.chestpubs.org/content/suppl/2009/03/19/chest.07-2800.DC1.html>

BLUE Protocol¹

- Acronym for Bedside Lung Ultrasound in Emergency
- “When your patient is blue, promptly perform a blue protocol”

¹Lichtenstein DA et al. Chest 2008; 134:117–125

A Profile

The *A profile* -- anterior predominant bilateral A lines associated with lung sliding (with possible focalized B lines).

The A' profile is an A profile with abolished lung sliding and without lung point.

B Profile

The *B profile* designates anterior-predominant bilateral B lines associated with lung sliding (with possible focalized A lines).

The B' profile is a B profile with abolished lung sliding.

AB Profile

The A/B profile designates anterior predominant B lines on one side, predominant A lines on the other.

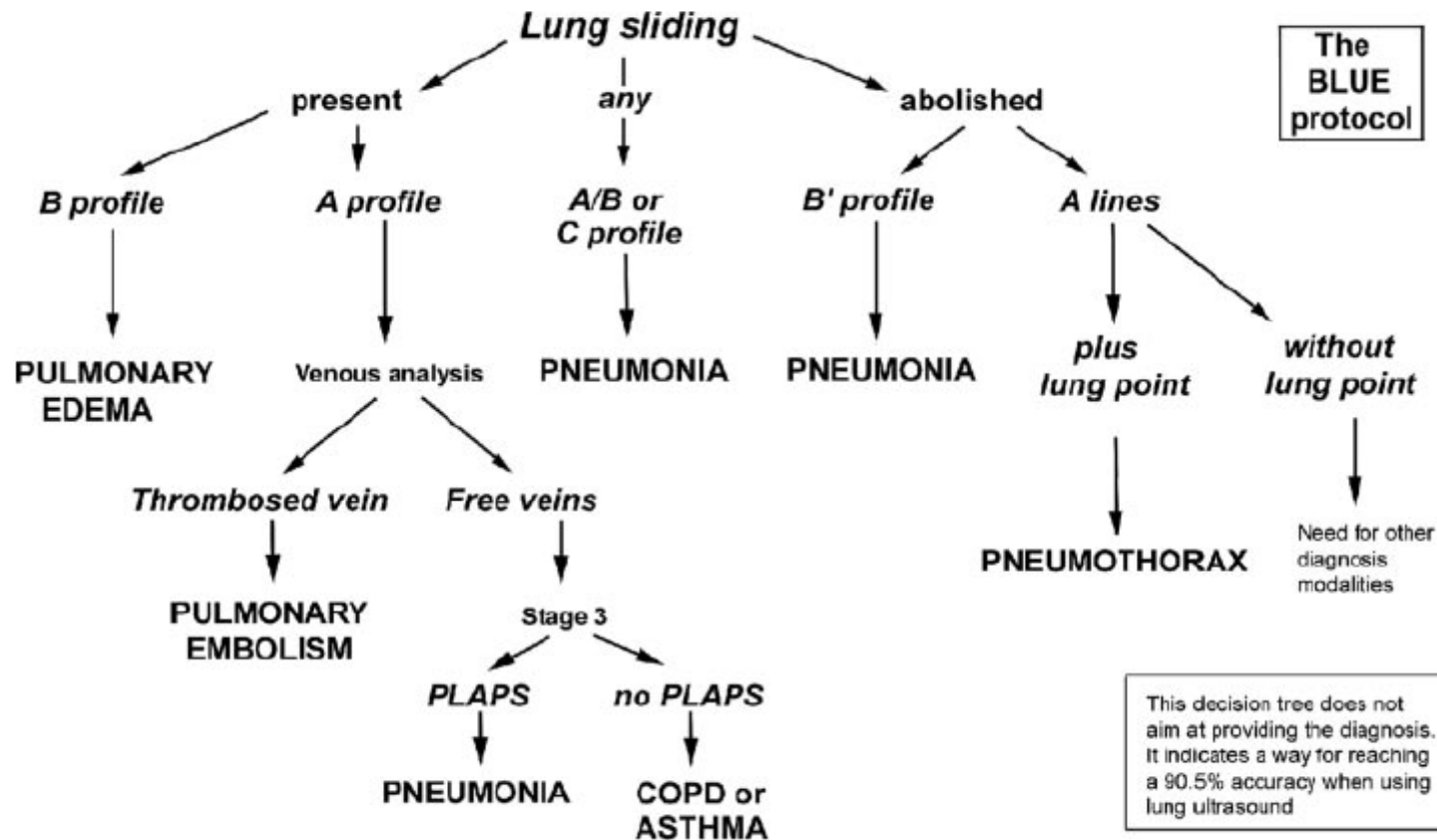
PLAPS

A lateral subposterior search for posterolateral alveolar and/or pleural syndrome (PLAPS)

C Profile

- *The C profile designates anterior alveolar consolidation(s).*

BLUE Protocol



Evaluation of thoracic cavity for Pleural Effusion

- Done by using the hepatorenal and splenorenal views used for the FAST examination
- Correlated to other findings on lung ultrasound

USG in shock

Approach

- Ruling in/out certain common conditions:
 - Hypovolemia
 - LV dysfunction/ myocardial infarction
 - Pneumothorax
 - Cardiac tamponade
 - Pulmonary thromboembolism

RUSH Exam

- Acronym for Rapid Ultrasound in Shock
- 3 steps:
 - Evaluation of the Pump
 - Evaluation of the Tank
 - Evaluation of the Pipes

Aortic Aneurysm

- Measurements should be obtained in the short axis, measuring the maximal diameter of the aorta from outer wall to outer wall, and should include any thrombus present in the vessel.
- A measurement of greater than 3 cm is abnormal and defines an abdominal aortic aneurysm
- Smaller aneurysms may be symptomatic, although rupture is more common with aneurysms measuring larger than 5 cm

Approach in Respiratory Failure

- Any patient with dyspnea:
 1. Carry out a lung USG and look at pleural spaces
 2. Look at the heart (pericardial effusion, LV function, right heart strain)
 3. Compression USG if PE suspected
 4. Look at IVC for vascular volume status

Approach in Shock

- Any patient with shock:
 1. Look at the heart (pericardial effusion, LV function, right heart strain)
 2. Look at IVC for vascular volume status
 3. Look for intraabdominal fluid (FAST esp in trauma pts)
 4. Look at aorta
 5. Carry out a lung USG and look at pleural spaces
 6. Compression USG if PE suspected

Summary

- USG is a powerful tool in the hands of a physician
- Can provide instant diagnosis of the cause of respiratory failure and shock at the bedside in an ICU